

Case Based Urology Learning Program

Resident's Corner: *UROLOGY*

Case Number 23

Case Based Urology Learning Program

Editor: Steven C. Campbell, MD PhD
Cleveland Clinic

Associate Editors: Jonathan H. Ross, MD
Rainbow Babies & Children's Hospital, UH
David A. Goldfarb, MD
Cleveland Clinic
Howard B. Goldman, MD
Cleveland Clinic

Manager: Nikki Williams
Cleveland Clinic

Case Contributors: Jonathan H. Ross, MD
Rainbow Babies & Children's Hospital, UH

You are called to the nursery to see a 2-day-old boy who was born with a lumbar myelomeningocele.

What is the difference between a meningocele, a myelomeningocele, and a lipomyelomeningocele?

What is the difference between a meningocele, a myelomeningocele, and a lipomyelomeningocele?

Myelodysplasia is a generic term referring to a failure of a portion of the spinal column to fuse with herniation of spinal cord material through the defect. A meningocele refers to herniation of the meninges with no neural elements extending beyond the confines of the vertebral canal. In a myelomeningocele, neural elements evaginate with the meninges. In a lipomyelomeningocele there is fatty tissue associated with the spinal cord which herniates with the neural elements and meninges.

How does the bony vertebral level of the defect (which may occur anywhere from the cervical spine to the scrotum) correlate with the clinical neurological level and bladder function?

How does the bony vertebral level of the defect correlate with the clinical neurological level and bladder function?

The level of the bony defect correlates poorly with the clinical and neurological manifestations. Therefore, each child must be evaluated and their neurological deficit and bladder characteristics defined by testing rather than assumptions based on the level of the bony lesion.

The neurosurgeons repair the myelomeningocele and predict the patient will be in the hospital for 2 more days.

What intervention would you recommend prior to discharge?

What intervention would you recommend prior to discharge?

The patient should be started on intermittent catheterization (IC) as most babies will have urinary retention secondary to spinal shock following back closure. The parents may discontinue IC once catheterized volumes become small.

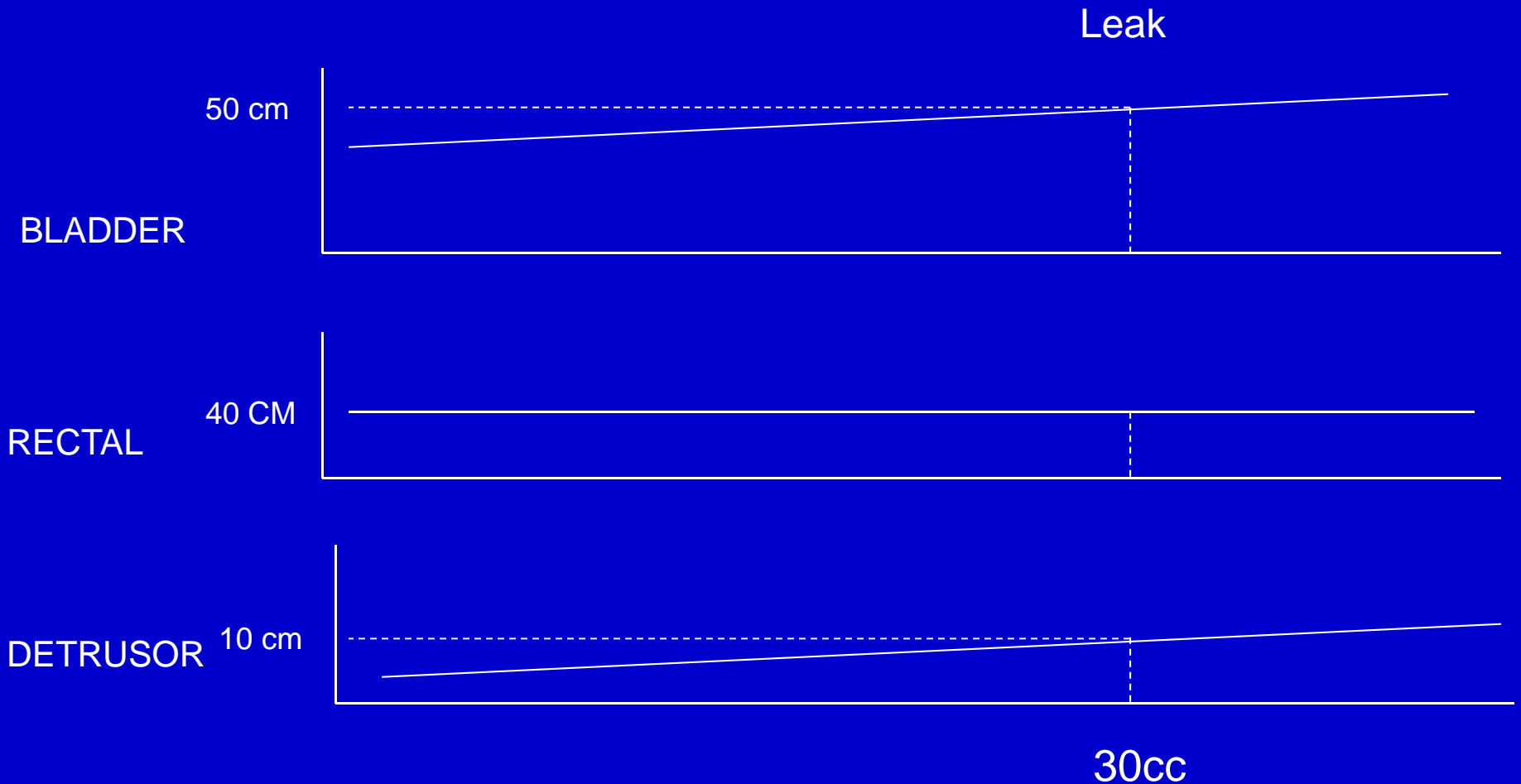
The patient is scheduled to return to the office at 6 weeks of age.

What studies would you obtain at that visit?

What studies would you obtain at that visit?

An ultrasound of the kidneys and bladder, a voiding cystourethrogram (VCUG) and urodynamic study should be obtained. The timing for initial urodynamic evaluation is controversial. Some argue for very early studies so that high-risk bladders can be identified and treated promptly. Others argue that meaningful urodynamics are difficult to obtain in small infants and that, in any case, bladder function will change rapidly in the first months of life making very early urodynamics quickly obsolete. In any case, the initial urodynamic study should be obtained sometime in the first several months of life.

This patient's ultrasound of the kidneys is normal and the VCUG shows a smooth bladder with an open bladder neck and no vesicoureteral reflux. A schematic of his urodynamics is shown here:



What are the important urodynamic findings?

What are the important urodynamic findings?

He has a mild decrease in bladder compliance with no uninhibited contractions and a detrusor leak point pressure of 10 cm of water (the detrusor pressure at which he begins to leak).

What is the most common urodynamic finding in patients with spina bifida and what is the significance of this patient's leak point pressure?

What is the most common urodynamic finding in patients with spina bifida and what is the significance of this patient's leak point pressure?

Detrusor sphincter dyssynergia (DSD) is the most common urodynamic finding in patients with spina bifida. DSD refers to a failure of the urethral sphincter to relax during bladder contractions. The leak-point pressure is a surrogate for the maximum storage pressure and the degree of any DSD that may be present. It has been shown that significant DSD and a leak point pressure of greater than 40 cm of water pressure portend a high risk for upper tract deterioration.

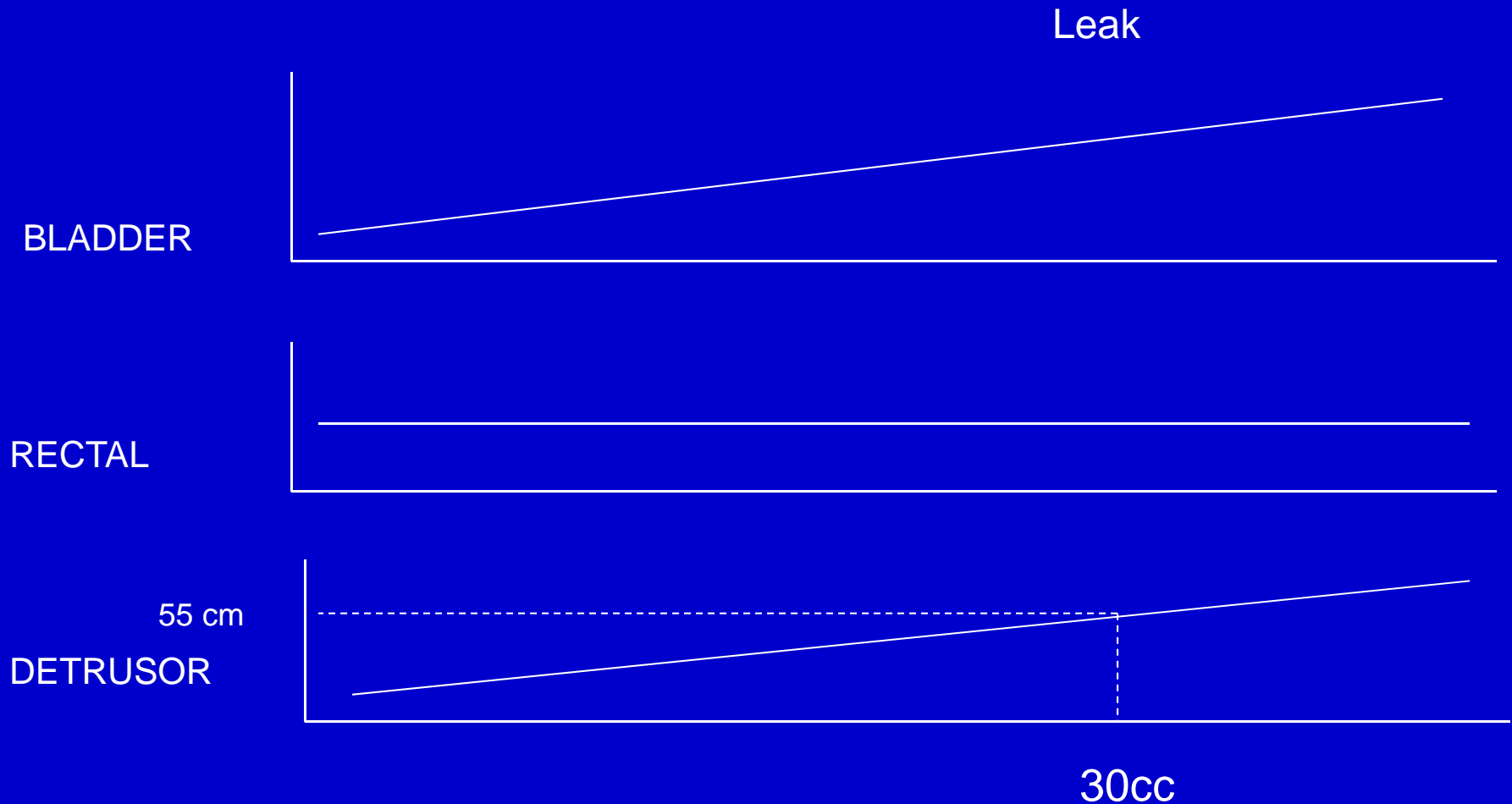
Since this patient's detrusor leak point pressure is low, his risk of developing hydronephrosis and/or reflux is small.

What further evaluation, intervention,
and/or follow-up would you
recommend?

What further evaluation, intervention, and/or follow-up would you recommend?

Because he has a low risk bladder, no intervention is needed at this point. Some authors favor early institution of IC anyway because a large majority of patients will ultimately require it; they consider it preferable to have the patient and family establish the habit and practice early. Other authors argue that early initiation of IC before it is needed adds an unnecessary burden to the family which is already dealing with many complicated issues in the newborn period.

You and the family decide not to intervene at this point and you recommend a follow-up ultrasound and urodynamic study in 3 months. At that time the ultrasound is again normal and the urodynamic study is represented schematically here:



What are the significant findings and what further evaluation, treatment, and/or follow-up would you recommend?

What are the significant findings and what further evaluation, treatment, and/or follow-up would you recommend?

The patient's urodynamics have changed, now demonstrating worse bladder compliance and a detrusor leak point pressure of 55 cm of water. Although the ultrasound is normal, the patient is at high risk for deterioration and so you recommend institution of IC and oral oxybutynin at a dose of 0.5 mg/kg/day divided in 3 doses.

You recommend the patient return in 2 months for reassessment to see if the therapy has been effective. Unfortunately, 2 months later the urodynamics have not changed significantly and the ultrasound now shows bilateral mild to moderate hydronephrosis.

List 4 options for further treating the patient's high bladder pressures without major surgery.

List 4 options for further treating the patient's high bladder pressures without major surgery.

Additional treatments to improve bladder compliance include the intravesical instillation of oxybutynin (5mg BID in addition to the oral oxybutynin), overnight catheter drainage of the bladder, Botox injection of the bladder, or aggressive urethral dilation in the operating room. Urethral dilation has been shown to cause a reflex improvement in bladder compliance and capacity; it does not, as one might suppose, relieve pressures by harming sphincteric function.

Despite attempting some or all of these interventions, the infant's bladder remains hostile and in the interval he has developed recurrent febrile urinary tract infections, progressive hydronephrosis, and new vesicoureteral reflux on VCUG. The baby is now 7 months old.

What intervention would you recommend at this point?

What intervention would you recommend at this point?

This patient should undergo a vesicostomy. While it is rare for infant bladders to behave in such a hostile fashion despite aggressive treatment, when it does happen, the upper tracts must be protected. In an older child, a bladder augmentation would be appropriate, but this is not usually employed in infants.

This patient undergoes a vesicostomy and his hydronephrosis resolves and his urinary tract infections cease.

What are the most common complications of a vesicostomy and how might they be prevented?

What are the most common complications of a vesicostomy and how might they be prevented?

Bladder prolapse and stomal stenosis are the most common complications. Prolapse is avoided by performing the vesicostomy at the dome of the bladder. Stomal stenosis is prevented by creating an adequate opening in the bladder dome; some surgeons also recommend creating a V or U flap incision in the skin so that the bladder opening may be spatulated.

This patient's vesicostomy heals well.

What will your long-term plan be for
this child?

What will your long-term plan be for this child?

He should undergo periodic ultrasounds and examinations to be sure that his vesicostomy continues to drain effectively. When he reaches approximately 5 years of age, if his development is otherwise normal and he wishes to get out of diapers, then the vesicostomy may be closed. Given his history, once the vesicostomy is closed, he will almost certainly require aggressive bladder management to prevent recurrent hydronephrosis and reflux, very possibly including a bladder augmentation.

Selected Reading

Snodgrass WT, Gargollo P. Urologic care of the neurogenic bladder in children. *Urol Clin N Am* 2010;37:207-14.

Topic:

Pediatric Urology/Neoplasms/Embryology

Subtopics:

Myelodysplasia and Neurogenic Bladder